

CLINICAL PRACTICE

## Bell's Palsy

Donald H. Gilden, M.D.

*This Journal feature begins with a case vignette highlighting a common clinical problem. Evidence supporting various strategies is then presented, followed by a review of formal guidelines, when they exist. The article ends with the author's clinical recommendations.*

**A healthy 50-year-old man notices that his face is drooping on the right side. On examination, facial asymmetry is evident, and some saliva has accumulated on the right side of the patient's mouth. When the patient attempts to close his eyes, his right eye does not close, although it rolls upward, and he is unable to show his teeth or inflate his cheek on the right. How should the patient be evaluated? Does he need immediate treatment?**

### THE CLINICAL PROBLEM

The most common causes of the abrupt onset of unilateral facial weakness are stroke and Bell's palsy. The patient's history and neurologic examination will determine whether facial weakness is central or peripheral. If weakness is central, brain magnetic resonance imaging (MRI) is required to evaluate the patient for ischemia and for infectious and inflammatory diseases. Other tests — such as examination of the cerebrospinal fluid, sedimentation rate, and glucose level; a blood count; and serologic studies to identify syphilis, the human immunodeficiency virus (HIV), and vasculitis — may be necessary.

If facial weakness is peripheral, no apparent cause will be found in most instances (in the case of Bell's palsy), and no tests are immediately indicated. The incidence of Bell's palsy is 20 to 30 cases per 100,000 people per year<sup>1</sup>; it accounts for 60 to 75 percent of all cases of unilateral facial paralysis.<sup>2</sup> The sexes are affected equally. The median age at onset is 40 years, but the disease may occur at any age.<sup>3</sup> The incidence is lowest in children under 10 years old, increases from the ages of 10 to 29, remains stable at the ages of 30 to 69, and is highest in people over the age of 70. The left and right sides of the face are involved with equal frequency. Most patients recover completely, although some have permanent disfiguring facial weakness.<sup>4</sup> Poor prognostic factors include older age,<sup>1</sup> hypertension,<sup>5</sup> impairment of taste,<sup>6</sup> pain other than in the ear, and complete facial weakness.<sup>7</sup> In the first three days, electrical studies reveal no changes in involved facial muscles, whereas a steady decline in electrical activity is often noted on days 4 to 10. When excitability is retained, 90 percent of patients recover completely; in the absence of excitability, only 20 percent of patients recover completely.<sup>8,9</sup>

Other causes of acquired peripheral facial weakness are much less common. Associated conditions include diabetes mellitus, hypertension, HIV infection, Lyme disease, the Ramsay Hunt syndrome (facial palsy with zoster oticus caused by varicella-zoster virus), sarcoidosis, Sjögren's syndrome, parotid-nerve tumors, eclampsia, and amyloidosis. Peripheral-facial-nerve palsy has also been reported among recipients of inactivated intranasal influenza vaccine.<sup>10</sup>

Bell's palsy rarely recurs. Recurrent or bilateral facial palsy should prompt consideration of myasthenia gravis or lesions at the base of the brain, where the facial nerve ex-

From the Departments of Neurology and Microbiology, University of Colorado Health Sciences Center, Denver. Address reprint requests to Dr. Gilden at the University of Colorado Health Sciences Center, 4200 E. 9th Ave., Mail Stop B182, Denver, CO 80262, or at don.gilden@uchsc.edu.

N Engl J Med 2004;351:1323-31.

Copyright © 2004 Massachusetts Medical Society.

its the pons; such types of palsy occur in lymphoma, sarcoidosis, and Lyme disease.<sup>11</sup> In rare cases, patients with inflammatory demyelinating polyneuropathy (the Guillain-Barré syndrome) present with bilateral facial palsy but relatively little weakness of the extremities. In immunocompetent people, the Ramsay Hunt syndrome is neither recurrent nor bilateral.

#### STRATEGIES AND EVIDENCE

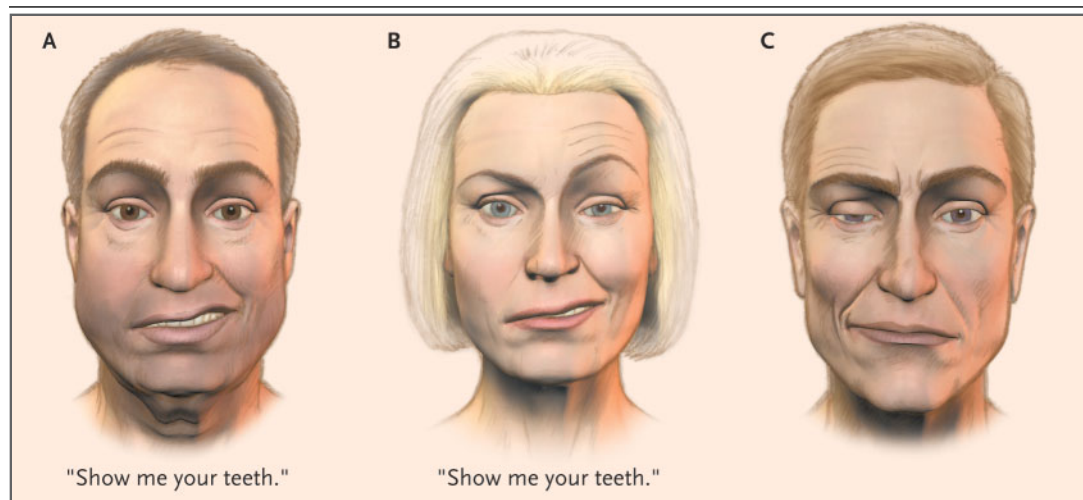
##### DIAGNOSIS

The first step in diagnosis is to determine whether facial weakness is due to a problem in the central nervous system or one in the peripheral nervous system. This is done rapidly with observation and a few questions (Fig. 1, 2, and 3 and Table 1). Central weakness of the unilateral lower facial area (Fig. 1A), which is always due to a lesion above the level of the facial nucleus in the pons of the contralateral hemisphere, is explained by the fact that cells of the facial nucleus that innervate the lower face receive corticobulbar fibers primarily from the contralateral cerebral hemisphere. In contrast, cells of the facial nucleus that innervate the upper face

receive corticobulbar fibers originating from both cerebral hemispheres. Thus, a unilateral lesion in the cortex or underlying corticobulbar fibers usually produces contralateral voluntary central-type facial paralysis and a contralateral hemiplegia but does not affect salivary and lacrimal secretions or the sense of taste (Table 2).

Peripheral facial palsy, or a weakness or paralysis of all muscles of facial expression (Fig. 1B), is usually due to a lesion of the ipsilateral facial nerve but can also be produced by a lesion of the ipsilateral facial nucleus or facial nerve in the pons. Although it appears paradoxical that a “central” lesion in the pons produces peripheral facial weakness, the nomenclature is not likely to change. Facial weakness is best demonstrated by the patient’s response to the requests “Close your eyes” (for testing the upper facial area) and “Show me your teeth” (for testing the lower facial area). Denervation of the orbicularis oculi muscles will result in the inability of the patient to close the eyelids effectively, and denervation of the risorius muscle will result in limited retraction of the angle of the mouth (Fig. 1B).

Hyperacusis results from paralysis of the stape-



**Figure 1. Central and Peripheral Facial Weakness.**

In response to the request “Show me your teeth,” subjects in both Panel A and Panel B demonstrate right lower facial weakness. The man in Panel A has central facial weakness, as demonstrated by the furrows on both sides of the forehead, indicating intact upper facial muscles bilaterally, and he can close both eyes. The woman in Panel B has no furrows on the right side of the forehead, and her right eye is open wider than her left, indicating weak right upper facial muscles. She has peripheral facial weakness caused by a lesion of the facial nerve or in the pons. The man in Panel C has right hemifacial spasm, which can develop not only after peripheral facial paralysis but also with any space-occupying lesion (e.g., a tumor or an ectatic artery) that irritates the facial nerve. Hemifacial spasm produces contraction of his orbicularis oculi muscles, with eye closure and retraction of the muscles of the right lower face. Casual inspection may give the false impression of facial weakness on the opposite (left) side.

dius muscle, which dampens vibrations of the ear ossicles and causes sounds to be abnormally loud on the affected side; there is no hearing loss. Also, because the nervus intermedius carries parasympathetic fibers that stimulate salivation and lacrimation, patients with lesions proximal to the geniculate ganglion often have a permanent loss of taste and are unable to produce tears (Fig. 4 and Table 2). Rapid recognition of the latter symptom is important, since these patients require artificial tears to lubricate the cornea and may need to have the eye taped shut to prevent drying and infection. Peripheral facial weakness may be confused with hemifacial spasm, in which the corner of the mouth is drawn up and the eye is partially or completely closed because of involuntary contraction of the risorius and orbicularis oculi muscles (Fig. 1C). After acute facial paralysis, preganglionic parasympathetic fibers that previously projected to the submandibular ganglion may regrow and enter the

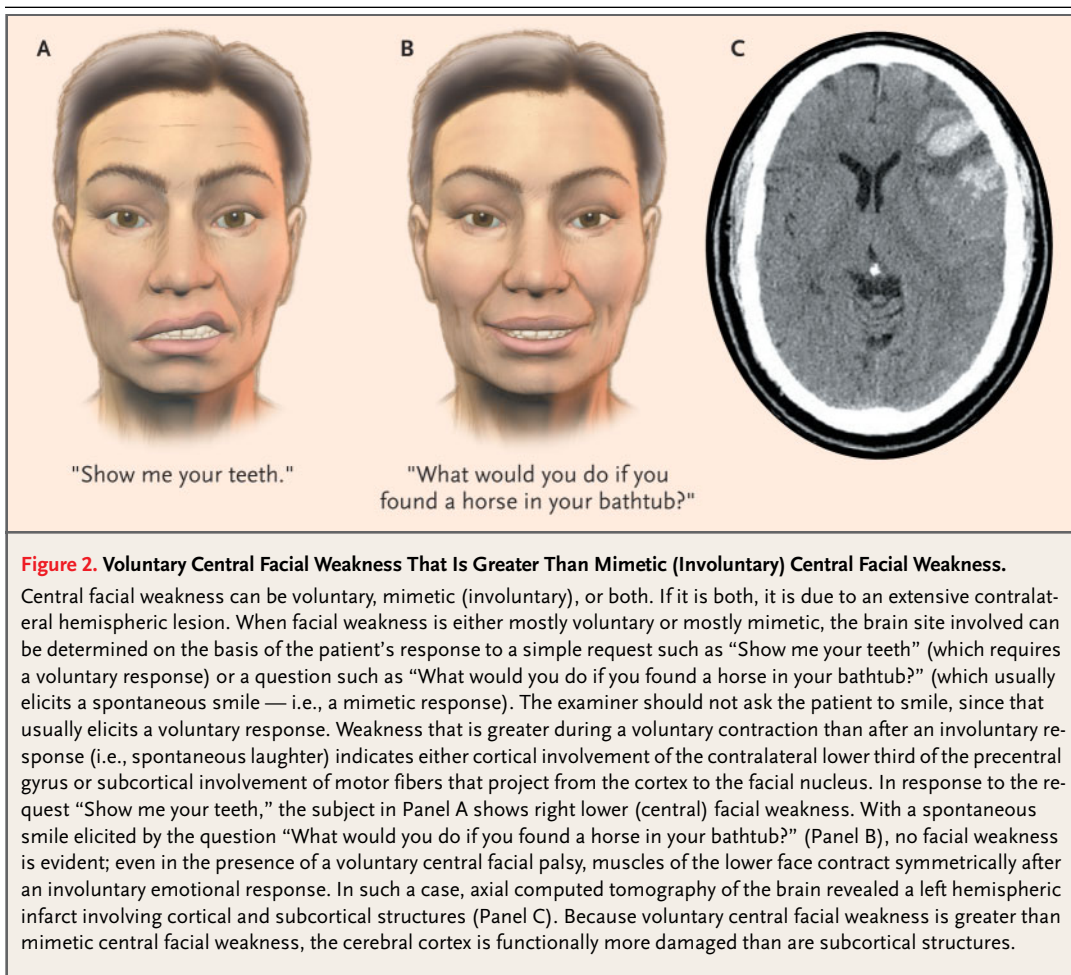
major superficial petrosal nerve. Such aberrant regeneration may lead to lacrimation after a salivary stimulus (the syndrome of crocodile tears).

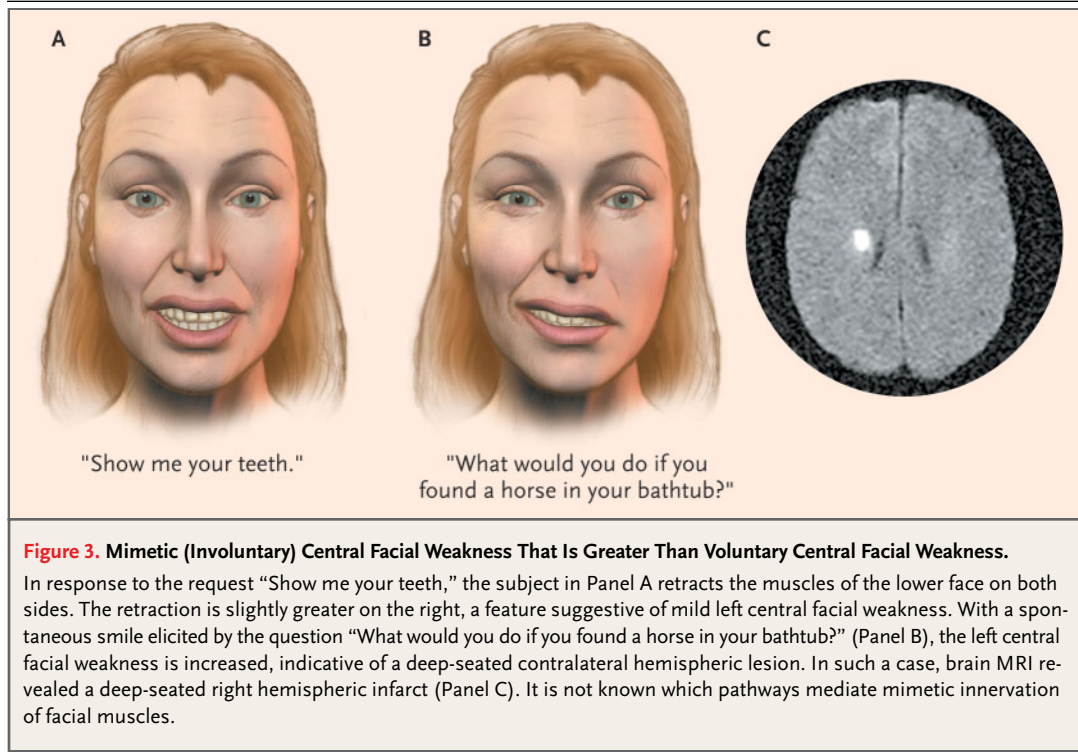
#### BRAIN MRI

Brain MRI is not routinely indicated, but if it is performed, the most common abnormality seen is contrast enhancement of the distal intracranial and labyrinthine segments of the facial nerve; the geniculate ganglion, as well as the proximal and distal tympanic and mastoid portions of the facial nerve, may also be involved (Fig. 5A).<sup>12</sup> A central pontine lesion (e.g., an infarct, as shown in Fig. 5B) may also produce facial weakness and is often associated with additional neurologic symptoms and signs.

#### ELECTRODIAGNOSTIC STUDIES

Incomplete return of facial motor function and synkinesis (involuntary movement of facial mus-





cles accompanying voluntary facial movement) are long-term sequelae in some patients. These sequelae are predicted by a lack of early clinical improvement in complete facial paralysis and by results of electroneurography; such testing may be clinically useful in patients with complete paralysis. Electroneurography uses a maximal electrically evoked stimulus and recording technique to mea-

sure the amplitude of the compound action potential of the facial muscle<sup>13</sup>; the extent of nerve degeneration can be determined by comparing the paralyzed side of the face with the normal side. After facial-nerve compression or complete transection by trauma, axonal degeneration is not evident for a few days. Thus, electrical testing should not be performed until three days after the onset of complete paralysis.

Among patients who do not have 90 percent degeneration within the first three weeks, 80 to 100 percent regain excellent function, with a grade of either 1 (normal strength) or 2 (minimal facial weakness) on the House–Brackmann scale. Among patients who have 90 percent or more degeneration within the first three weeks, only 50 percent have a good recovery of facial function.<sup>14</sup> The rate of degeneration also predicts prognosis; for example, patients with 90 percent degeneration on day 5 have a worse prognosis than those with 90 percent degeneration on day 14. Electroneurography is most useful when performed within two weeks after a complete loss of voluntary facial function.

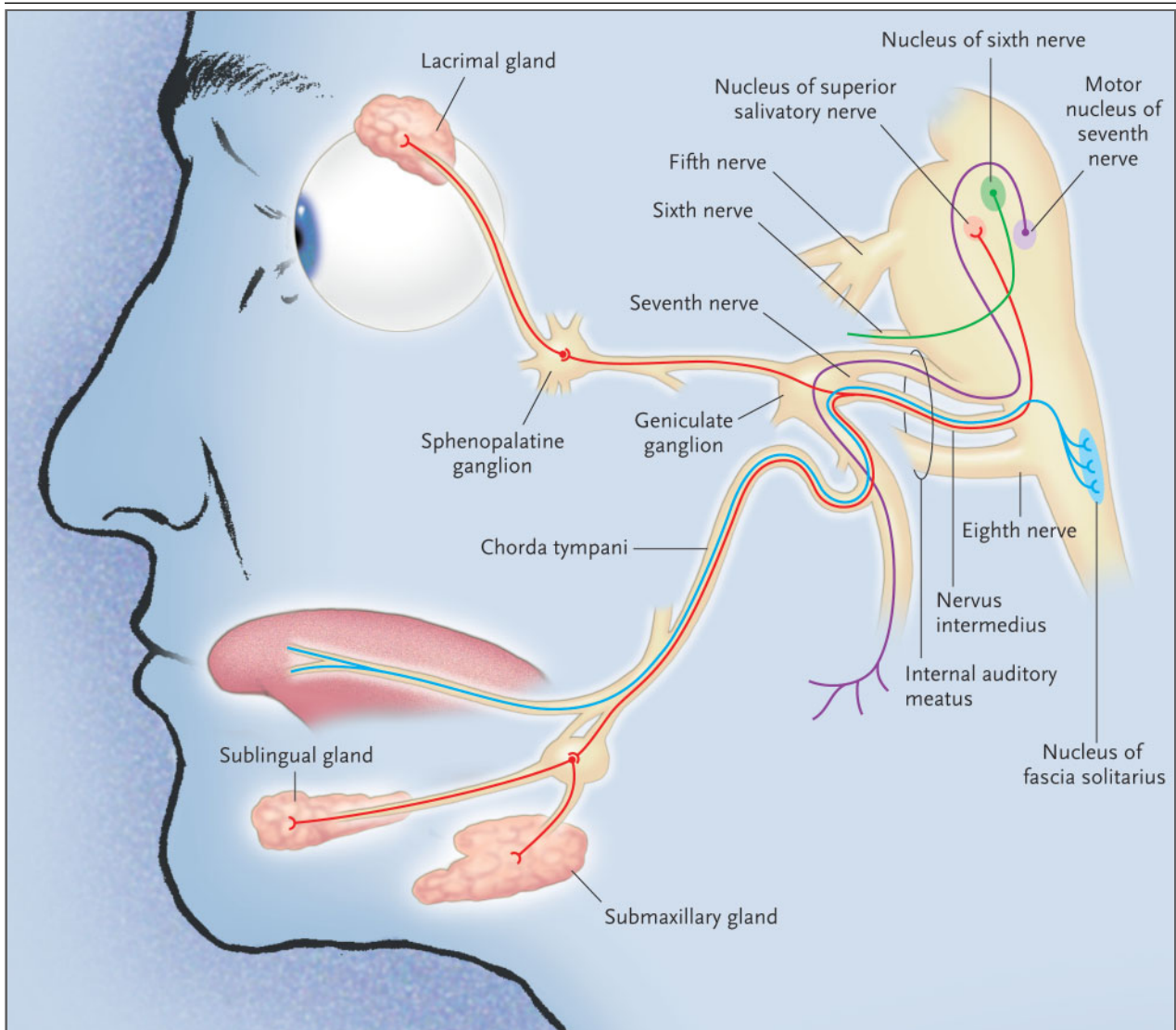
**MEDICAL TREATMENT**

Any evaluation must consider that 71 percent of untreated patients recover completely and 84 per-

**Table 1. Diagnosis of Peripheral or Central Facial Weakness and Site of Injury.**

Characteristic	Peripheral*	Central†	
		Voluntary	Mimetic
Weakness in the upper facial area	Yes	No	No
Weakness in the lower facial area	Yes	Yes‡	Yes§
Site of injury¶	Peripheral nerve, pons	Contralateral hemisphere	

\* The lesion is ipsilateral to the facial weakness.  
 † The lesion is contralateral to the weakness in the lower facial area.  
 ‡ The weakness in the lower facial area is greater when the patient responds to the request “Show me your teeth” than when the patient smiles spontaneously.  
 § The weakness in the lower facial area is greater when the patient smiles spontaneously than when the patient responds to the request “Show me your teeth.”  
 ¶ A facial twitch or spasm preceding the onset of paralysis suggests a tumor, usually outside the pons, that has irritated the facial nerve.



**Figure 4. Functional Anatomy of the Facial Nerve and Diagnosis of Peripheral Facial Weakness.**

Although the facial nerve has a long, circuitous path, the site of involvement can be deduced from the patient's clinical deficit. The facial, or seventh cranial, nerve is predominantly motor in function. Its nucleus is in the caudal pons. The facial nerve courses dorsomedially and encircles the nucleus of the abducens (sixth) cranial nerve. After bending around the abducens nucleus, the facial nerve lies close to the sixth nerve. The facial nerve exits the pons in the cerebellopontine angle close to the fifth, sixth, and eighth cranial nerves. The eighth nerve, the motor root of the seventh nerve, and the nervus intermedius (the sensory and parasympathetic root of the facial nerve) enter the internal auditory meatus. Sensory cells located in the geniculate ganglion continue distally as the chorda tympani nerve, which carries taste fibers. Peripheral fibers of the nervus intermedius portion of the facial nerve initiate salivary, lacrimal, and mucous secretion.

cent achieve near-normal function.<sup>5</sup> Thus, the 20 to 30 percent who do not recover fully remain the focus of treatment. Various findings provide a rationale for early and aggressive treatment. First, for more than half a century, surgeons who perform decompression operations on patients with Bell's palsy have described facial-nerve swelling,<sup>15</sup> a find-

ing confirmed by MRI. Second, the detection of herpes simplex virus (HSV) in endoneurial fluid in patients with Bell's palsy<sup>16</sup> has implicated the virus in the pathogenesis of the disease.

Numerous studies of patients with Bell's palsy have compared treatment with glucocorticoids with treatment with acyclovir or placebo; studies com-

**Table 2. Clinical and Anatomical Features of Facial-Nerve Damage.**

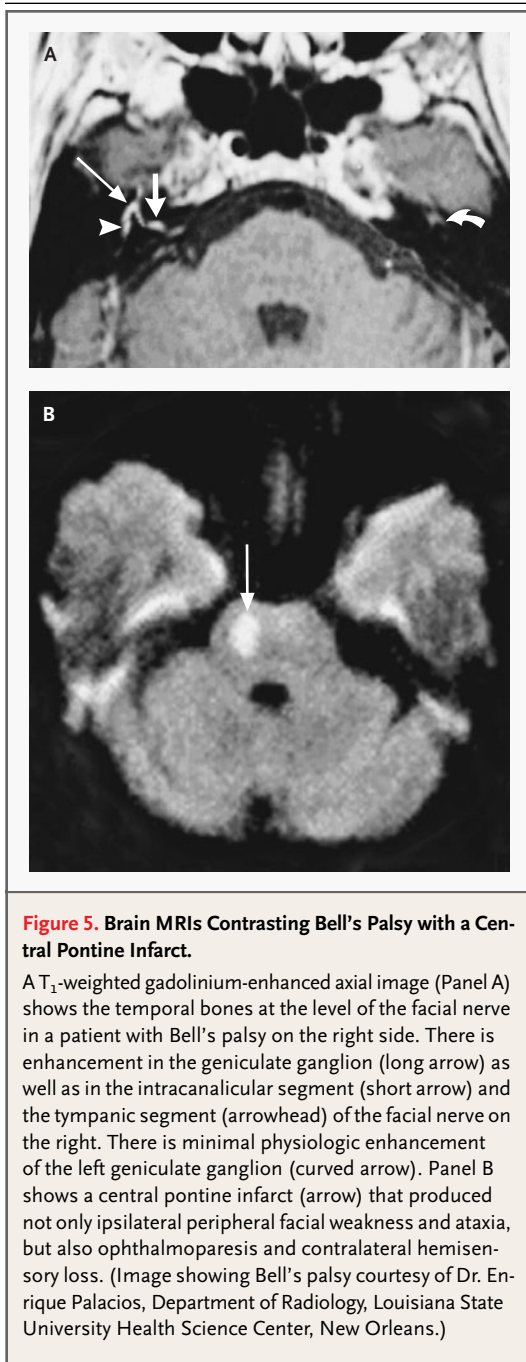
Site of Damage	Facial-Nerve Signs	Common Associated Features	Common Causes
Cortex, subcortical region	Contralateral central facial weakness; lacrimation, salivation, and taste intact	Contralateral hemiparesis and spasticity	Cortical or subcortical infarct
Pons	Ipsilateral peripheral facial weakness; lacrimation, salivation, and taste intact	Contralateral hemiparesis, sensory loss, ataxia, nystagmus, ipsilateral abducens palsy, ophthalmoparesis	Pontine infarction, glioma, multiple sclerosis
Cerebellopontine angle	Ipsilateral peripheral facial weakness; lacrimation, salivation, and taste usually intact	Tinnitus, facial numbness, ataxia, nystagmus	Acoustic or facial neuroma, meningioma, cholesteatoma, lymphoma, aneurysm, sarcoïdosis
Facial nerve in internal auditory canal proximal to or involving geniculate ganglion	Ipsilateral peripheral facial weakness; lacrimation, salivation, and taste likely to be involved	Tinnitus, nystagmus, hearing loss	Bell's palsy, the Ramsay Hunt syndrome, acoustic or facial neuroma
Facial nerve distal to internal auditory canal and geniculate ganglion	Ipsilateral peripheral facial weakness; lacrimation intact but salivation and taste impaired	Tinnitus, nystagmus, hearing loss	Bell's palsy, temporal-bone fracture, cholesteatoma or glomus tumor, middle-ear infection
Facial nerve in stylomastoid foramen	Ipsilateral peripheral facial weakness; lacrimation, salivation, and taste intact	Head injury, parotid mass	Head injury, parotid tumor

paring antiviral treatment with no treatment have not been performed. One large observational study compared 194 patients treated with prednisone for 12 days (40 mg for 4 days tapered to 8 mg daily by day 12) with 110 untreated patients in a historical control group; complete facial paralysis was observed at follow-up in no patient in the treated group as compared with 10 percent of patients in the untreated group.<sup>17</sup> A later randomized, double-blind, placebo-controlled trial demonstrated a higher rate of recovery of facial function (as assessed by the House–Brackmann grading system) among 35 patients treated with prednisone (30 mg twice daily for five days tapered to 5 mg daily by day 10), as compared with 41 patients given placebo; all the patients in the study were treated within five days after the onset of paralysis.<sup>18</sup> In diabetic patients with complete Bell's palsy who were treated with prednisolone (200 mg for two days tapered to 70 mg by day 7), the rate of cure (i.e., a return to normal facial function) was 97 percent, as compared with 58 percent in untreated patients ( $P < 0.01$ ).<sup>19</sup>

Meta-analyses have also been performed comparing glucocorticoids with placebo. One such analysis, which combined findings from four published studies (one of which was neither blinded

nor placebo-controlled), showed significant improvement of facial weakness with glucocorticoid therapy.<sup>20</sup> A second meta-analysis (including only randomized, controlled trials) showed that treatment with glucocorticoids that was started within seven days after the onset of complete facial paralysis increased the likelihood of complete facial recovery by 17 percent ( $P = 0.005$ ), as compared with placebo.<sup>21</sup>

However, not all studies have shown a benefit to glucocorticoid therapy. In one controlled, double-blind trial, rates of recovery were not significantly different between the prednisone and placebo groups after six months<sup>22</sup>; this finding was considered to be potentially attributable to a small sample as well as to a high percentage of patients with initially severe weakness. Another study of 239 patients with Bell's palsy who were randomly assigned to receive either prednisone or placebo showed complete recovery of facial strength in 88 percent of glucocorticoid-treated patients and in 80 percent of the patients in the control group, a difference that was not statistically significant,<sup>23</sup> which is perhaps explained by the fact that patients were followed until complete recovery or for one year.



One randomized trial with no placebo group included 101 patients and compared oral prednisone (1 mg per kilogram of body weight for 10 days tapered to 0 by day 16) with acyclovir (800 mg three times daily for 10 days); the administration of both study drugs was initiated within 4 days after the onset of facial weakness. This study indicated that at

three months or later, facial-muscle strength was better after treatment with prednisone than it was after treatment with acyclovir.<sup>24</sup> In another randomized, double-blind trial that included 99 patients, a combination of prednisone and acyclovir (the latter at a dose of 400 mg five times daily) was superior to a combination of prednisone and placebo in restoring the function of voluntary facial muscles ( $P=0.02$ ) and in preventing partial nerve degeneration ( $P=0.05$ ).<sup>25</sup> Overall, the data suggest that glucocorticoids decrease the incidence of permanent facial paralysis, although more studies are required to determine whether antiviral therapy confers additional benefit.

#### SURGICAL DECOMPRESSION

Some patients with Bell's palsy may be candidates for surgery. The facial nerve may be compressed (and its conduction blocked) at its narrowest point, the entrance to the meatal foramen, occupied by the labyrinthine segment and geniculate ganglion. Among 12 patients with facial-nerve paralysis who underwent decompression surgery, bulbous swelling of the facial nerve was seen proximal to the geniculate ganglion in 11, and intraoperative evoked-potential electromyography performed in 3 documented conduction block proximal to the geniculate ganglion.<sup>26</sup>

The role of surgical decompression in management remains controversial. In a prospective observational study of 31 patients with complete paralysis and 90 percent or more nerve degeneration as determined by electroneurography, 91 percent of those who underwent decompression had a good outcome (i.e., a grade 1 or 2 on the House-Brackmann scale) by the seventh month, as compared with 42 percent of those who were treated with glucocorticoids.<sup>27</sup> Other observational studies comparing outcomes at 6 to 36 months after prednisone treatment with outcomes after decompression<sup>28-31</sup> have not confirmed a benefit of surgery, however. Data from randomized trials are lacking to compare surgery with medical therapy, and available data are limited by small samples, possible bias in the selection of patients for surgery, the use of varying surgical approaches and systems to assess facial function, and a lack of blinding in studies assessing functional outcomes.

After decompression surgery, permanent unilateral deafness may occur, with estimates ranging from less than 1 percent<sup>27</sup> to 15 percent<sup>29</sup> of patients. Because severe degeneration of the facial

nerve is probably irreversible after 2 to 3 weeks,<sup>32</sup> decompression should not be performed 14 days or more after the onset of paralysis.

---

#### AREAS OF UNCERTAINTY

---

##### CAUSE OF BELL'S PALSY

Some cases of Bell's palsy have been attributed to ischemia from diabetes and arteriosclerosis, which helps to explain the increased incidence of Bell's palsy in elderly patients; the disorder is analogous to ischemic mononeuropathy of other cranial nerves in patients with diabetes.<sup>33,34</sup> However, HSV type 1 (HSV-1) is probably the cause of most cases of Bell's palsy. Virologic analysis of endoneurial fluid obtained during decompression surgery<sup>16</sup> revealed HSV-1 DNA in 11 of 14 patients with Bell's palsy. HSV-1 DNA appeared to be specific to Bell's palsy, since it was not found in anyone with the Ramsay Hunt syndrome or other neurologic diseases. The rising incidence of Bell's palsy with increasing age parallels seroconversion to HSV-1.<sup>35</sup> Because seropositivity to HSV is well established by adult life, when Bell's palsy is most common, the disease probably reflects virus reactivation from latency in the geniculate ganglion,<sup>36</sup> rather than primary infection. How the virus damages the facial nerve is uncertain.

##### TREATMENT

Large randomized, double-blind trials are needed to better assess the effectiveness of glucocorticoids, antiviral agents, or both as compared with placebo, as well as to assess the benefit of surgical decompression among patients considered to be at high risk for permanent paralysis.<sup>37</sup> In particular, studies are needed to determine the time after which medical treatment or surgery is of no value. Furthermore, additional data are needed to determine whether a combination of antiviral and corticosteroid therapy is better than treatment with corticosteroids alone. Of note is the recent observation that long-term recovery of peripheral vestibular function in patients with vestibular neuritis, a condition also attributed to HSV infection, is significantly improved by treatment with corticosteroids but not with valacyclovir.<sup>38</sup>

---

#### GUIDELINES

---

The Quality Standards Subcommittee of the American Academy of Neurology states that early treat-

ment with oral corticosteroids is probably effective in improving facial-function outcomes in Bell's palsy, that the addition of acyclovir to prednisone is possibly effective, and that insufficient evidence exists to recommend facial-nerve decompression.<sup>37</sup>

---

#### SUMMARY AND RECOMMENDATIONS

---

The first step in evaluating patients with acute facial paralysis is to determine whether the paralysis is central or peripheral. If it is peripheral without any apparent cause (and is thus Bell's palsy), and is diagnosed within one week after the onset of symptoms, as in the patient described in the vignette, no tests are indicated unless other cranial-nerve deficits develop (indicating more widespread disease), there is no recovery three to six weeks after the onset of symptoms, or a facial twitch or spasm preceded Bell's palsy (indicating continuous facial-nerve irritation suggestive of a tumor). The collective findings of facial-nerve swelling, MRI changes consistent with inflammation, and available data regarding clinical outcomes support the use of a short course of prednisone within 2 to 14 days after the onset of symptoms. Because Bell's palsy is associated with HSV infection, antiviral treatment may help, although data are lacking to show that such treatment speeds recovery or leads to a better long-term outcome. In the case described in the vignette, I would treat the patient with oral valacyclovir (1 g twice daily for seven days) or famciclovir (750 mg three times daily) and oral prednisone (1 mg per kilogram per day for seven days). Prednisone should be used cautiously in patients with diabetes, peptic ulcer disease, renal or hepatic dysfunction, or severe hypertension. Either valacyclovir or famciclovir is preferable to acyclovir because adherence to treatment is better than with acyclovir, which requires five daily doses of 800 mg. In children, the dose of prednisone and antiviral agents must be adjusted for weight. The same treatment can be given during pregnancy, although the safety of antiviral agents in pregnancy has not been established. There is no need to taper the dose of prednisone after only one week of treatment.

If complete facial paralysis is still present after one week of medical treatment, electroneurography should be performed. If electroneurography documents 90 percent nerve degeneration, decompression may be considered, although there are no data from clinical trials to support its use.<sup>27</sup> If de-

compression is performed, timing is critical. The destiny of the facial nerve in Bell's palsy is probably decided within the first two to three weeks after the onset of symptoms.<sup>32</sup> Finally, for patients with permanent facial paralysis, various surgical procedures exist for dynamic reconstruction of the facial nerve.<sup>39</sup>

Supported in part by grants from the National Institutes of Health (NS32623 and AG06127).

I am indebted to Helen MacFarlane for assistance with the figures; to Drs. Nadine Girard, Bodo Kress, Toshibumi Kinoshita, and Enrique Palacios for reviewing the section on brain MRI; to Dr. Steven Deitch for help with computer diagrams; to Drs. Steven Deitch, Deborah Hall, Adam Gilden Tsai, and Kenneth Tyler for a careful critique; to Marina Hoffman for editorial review; and to Cathy Allen for assistance in the preparation of the manuscript.

## REFERENCES

- Hauser WA, Karnes WE, Annis J, Kurland LT. Incidence and prognosis of Bell's palsy in the population of Rochester, Minnesota. *Mayo Clin Proc* 1971;46:258-64.
- Adour KK, Byl FM, Hilsinger RL Jr, Kahn ZM, Sheldon MI. The true nature of Bell's palsy: analysis of 1,000 consecutive patients. *Laryngoscope* 1978;88:787-801.
- Katusic SK, Beard CM, Wiederholt WC, Bergstralh EJ, Kurland LT. Incidence, clinical features, and prognosis in Bell's palsy, Rochester, Minnesota 1968-1982. *Ann Neurol* 1986;20:622-7.
- Peitersen E. The natural history of Bell's palsy. *Am J Otol* 1982;4:107-11.
- Adour KK, Wingerd J. Idiopathic facial paralysis (Bell's palsy): factors affecting severity and outcome in 446 patients. *Neurology* 1974;24:1112-6.
- Diamant H, Ekstrand T, Wiberg A. Prognosis of idiopathic Bell's palsy. *Arch Otolaryngol* 1972;95:431-3.
- Cawthorne T, Wilson T. Indications for intratemporal facial nerve surgery. *Arch Otolaryngol* 1963;78:429-34.
- Campbell EDR, Hickey RP, Nixon KH, Richardson AT. Value of nerve-excitability measurements in prognosis of facial palsy. *Br Med J* 1962;2:7-10.
- Richardson AT. Electrodiagnosis of facial palsies. *Ann Otol Rhinol Laryngol* 1963;72:569-80.
- Mutsch M, Zhou W, Rhodes P, et al. Use of the inactivated intranasal influenza vaccine and the risk of Bell's palsy in Switzerland. *N Engl J Med* 2004;350:896-903.
- Keane JR. Bilateral seventh nerve palsy: analysis of 43 cases and review of the literature. *Neurology* 1994;44:1198-202.
- Sartoretti-Schefer S, Wichmann W, Valavanis A. Idiopathic, herpetic, and HIV-associated facial nerve palsies: abnormal MR enhancement patterns. *AJNR Am J Neuroradiol* 1994;15:479-85.
- Gantz BJ, Gmuer AA, Holliday M, Fisch U. Electroneurographic evaluation of the facial nerve: method and technical problems. *Ann Otol Rhinol Laryngol* 1984;93:394-8.
- Fisch U. Total facial nerve decompression and electroneurography. In: Silverstein H, Norrel H, eds. *Neurological surgery of the ear*. Birmingham, Ala.: Aesculapius, 1977:31-3.
- Cawthorne T. The pathology and surgical treatment of Bell's palsy. *Proc R Soc Med* 1950;4:565-72.
- Murakami S, Mizobuchi M, Nakashiro Y, Doi T, Hato N, Yanagihara N. Bell palsy and herpes simplex virus: identification of viral DNA in endoneurial fluid and muscle. *Ann Intern Med* 1996;124:27-30.
- Adour KK, Wingerd J, Bell DN, Manning JJ, Hurley JP. Prednisone treatment for idiopathic facial paralysis (Bell's palsy). *N Engl J Med* 1972;287:1268-72.
- Austin JR, Peskind SP, Austin SG, Rice DH. Idiopathic facial nerve paralysis: a randomized double blind controlled study of placebo versus prednisone. *Laryngoscope* 1993;103:1326-33.
- Saito O, Aoyagi M, Tojima H, Koike Y. Diagnosis and treatment for Bell's palsy associated with diabetes mellitus. *Acta Otolaryngol Suppl* 1994;551:153-5.
- Williamson IG, Whelan TR. The clinical problem of Bell's palsy: is treatment with steroids effective? *Br J Gen Pract* 1996;46:743-7.
- Ramsey MJ, DerSimonian R, Holtel MR, Burgess LPA. Corticosteroid treatment for idiopathic facial nerve paralysis: a meta-analysis. *Laryngoscope* 2000;110:335-41.
- May M, Wette R, Hardin WB Jr, Sullivan J. The use of steroids in Bell's palsy: a prospective controlled study. *Laryngoscope* 1976;86:1111-22.
- Wolf SM, Wagner JH, Davidson S, Forsythe A. Treatment of Bell palsy with prednisone: a prospective, randomized study. *Neurology* 1978;28:158-61.
- De Diego JI, Prim MP, De Sarria MJ, Madero R, Gavilan J. Idiopathic facial paralysis: a randomized, prospective, and controlled study using single-dose prednisone versus acyclovir three times daily. *Laryngoscope* 1998;108:573-5.
- Adour KK, Ruboyanes JM, Von Doersten PG, et al. Bell's palsy treatment with acyclovir and prednisone compared with prednisone alone: a double-blind, randomized, controlled trial. *Ann Otol Rhinol Laryngol* 1996;105:371-8.
- Fisch U, Esslen E. Total intratemporal exposure of the facial nerve: pathologic findings in Bell's palsy. *Arch Otolaryngol* 1972;95:335-41.
- Gantz BJ, Rubinstein JT, Gidley P, Woodworth GG. Surgical management of Bell's palsy. *Laryngoscope* 1999;109:1177-88.
- Fisch U. Surgery for Bell's palsy. *Arch Otolaryngol* 1981;107:1-11.
- Brown JS. Bell's palsy: a 5 year review of 174 consecutive cases: an attempted double blind study. *Laryngoscope* 1982;92:1369-73.
- May M, Taylor FH. Bell's palsy: surgery based upon prognostic indicators and results. *Laryngoscope* 1981;91:2092-103.
- May M, Klein SR, Taylor FH. Idiopathic (Bell's) facial palsy: natural history defies steroid or surgical treatment. *Laryngoscope* 1985;95:406-9.
- Fisch U. Prognostic value of electrical tests in acute facial paralysis. *Am J Otol* 1984;5:494-8.
- Merwarth HR. The occurrence of peripheral facial paralysis in hypertensive vascular disease. *Ann Intern Med* 1942;17:298-307.
- Raff MC, Asbury AK. Ischemic mononeuropathy and mononeuropathy multiplex in diabetes mellitus. *N Engl J Med* 1968;279:17-22.
- Wentworth BB, Alexander ER. Seroepidemiology of infections due to members of the herpesvirus group. *Am J Epidemiol* 1971;94:496-507.
- Furuta Y, Takasu T, Sato KC, Fukuda S, Inuyama Y, Nagashima K. Latent herpes simplex virus type 1 in human geniculate ganglia. *Acta Neuropathol (Berl)* 1992;84:39-44.
- Grogan PM, Gronseth GS. Practice parameter: steroids, acyclovir, and surgery for Bell's palsy (an evidence-based review): report of the Quality Standards Subcommittee of the American Academy of Neurology. *Neurology* 2001;56:830-6.
- Strupp M, Zingler V, Arbusow V, et al. Methylprednisolone, valacyclovir, or the combination for vestibular neuritis. *N Engl J Med* 2004;351:354-61.
- Snyder MC, Johnson PJ. Facial nerve paralysis, dynamic reconstruction. (Accessed August 9, 2004, at <http://www.emedicine.com/plastic/topic218.htm>)

Copyright © 2004 Massachusetts Medical Society.